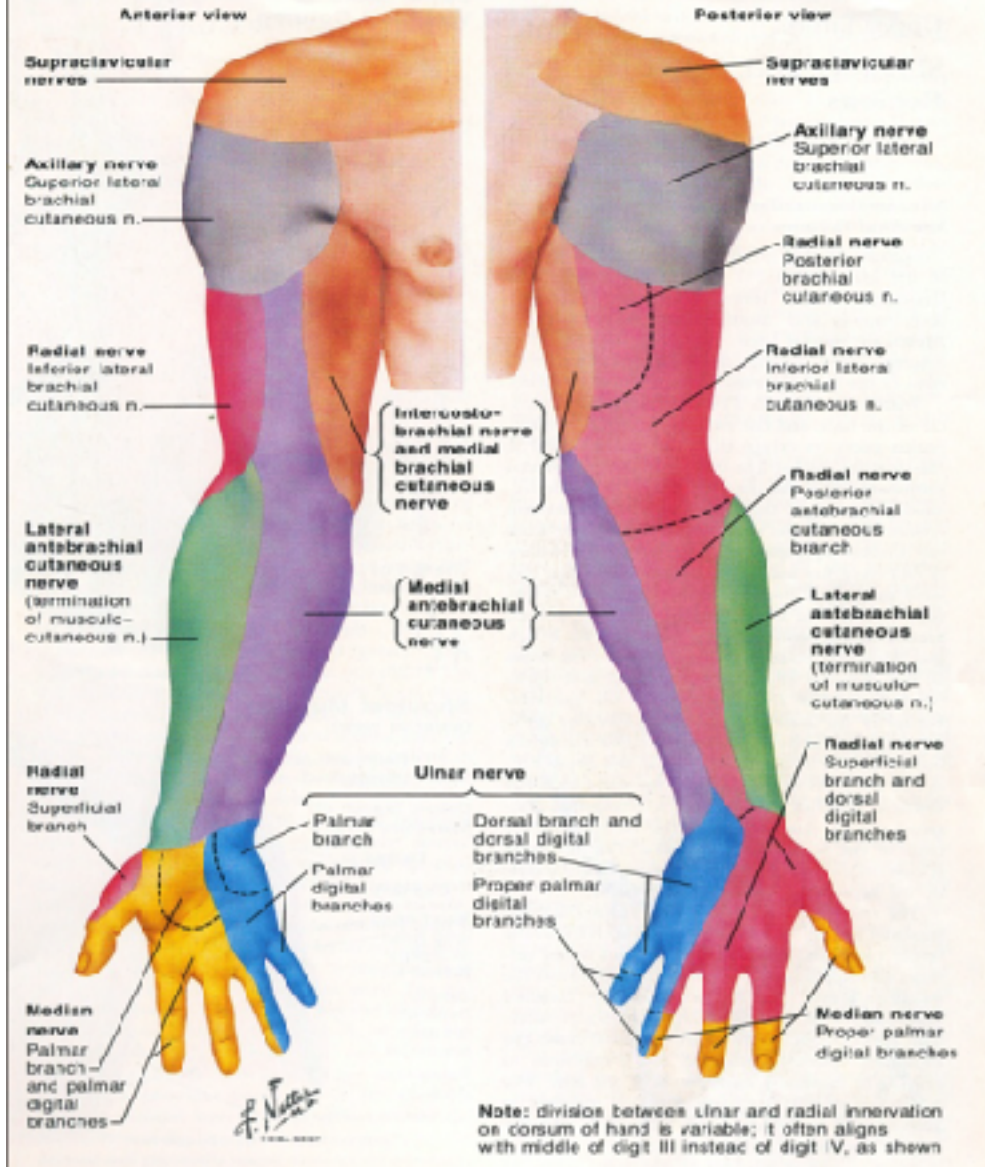


Cutaneous Innervation of Upper Limb



Note: division between ulnar and radial innervation on dorsum of hand is variable; it often aligns with middle of digit III instead of digit IV, as shown